



## PATIENT PRESENTING CLINICAL SIGNS

- Mealo Meara
- Previously admitted, discharged on 31/01 for inappetence/ suspected pancreatitis- ate well and went home. At home not eating much and not wanting to drink, o also struggling to medicate
  - Was already booked in for CT tomorrow for chest (suspected intrathoracic mass) and right forelimb (bony changes noted)
  - On plant based diet- but did eat chappy here- hx of skin issues but o is okay for him to have some meat if hes refusing all others.
- SPECIES  
Canine

## BREED COMPUTED TOMOGRAPHIC STUDY OF THE RIGHT THORACIC LIMB AND THORAX

Shih Tzu Plain and post contrast studies for the thorax and plain study available for the right forelimb are available for review.

## SEX COMPUTED TOMOGRAPHIC FINDINGS

M RIGHT THORACIC LIMB

## AGE

11yr

A monostotic aggressive osteolytic lesion affecting the distal metaphyseal region of the right radius is seen. The lesion is characterized by poorly defined moth-eaten to permeative osteolysis, cortical destruction and thinning with indistinct transition zone to the unaffected bone. No involvement of the radiocarpal joint is identified. The ulna is not affected. No pathological fracture is present at the time of imaging on the thorax.

## INTERPRETED BY

THORAX

Nele Eley (Ondreka),  
DVM Dr. med. vet.,  
DipECVDI

A solitary 7 mm sized soft tissue attenuating pulmonary nodule is present within the right caudal lung lobe suspicious for metastatic disease given the aggressive primary bone lesion. No additional pulmonary nodules are identified at the time of imaging.

## HOSPITAL NAME

Animal Trust  
Ellesmere

A chronic peritoneal pericardial diaphragmatic hernia with herniation of fat into the pericardial sac is seen with no evidence of acute inflammation, strangulation or compromise associated with the herniated tissue.

Mild enlargement of the right axillary lymph node is noted.

## REFERRING VET

Jenny Bowen Smith

## COMPUTED TOMOGRAPHIC DIAGNOSIS

- Monostotic aggressive osteolytic lesion of the distal right radius
- Solitary pulmonary nodule in the right caudal lung lobe suspicious for metastatic disease
- Mild right axillary lymphadenopathy
- Incidental chronic peritoneal pericardial diaphragmatic hernia with fat herniation only

## INVOICE

23749

## DATE

02/02/2026

## INTERPRETATION OF FINDINGS & FURTHER RECOMMENDATIONS

The imaging appearance of the monostotic osteolytic lesion of the distal right radius is aggressive and highly suspicious for primary bone neoplasia such as osteosarcoma, although other neoplasms are less likely. Infectious osteomyelitis can never be entirely excluded without sampling.



## PATIENT

Mealo Meara

The right axillary lymphadenomegaly may reflect reactive change or early metastatic disease.

The presence of a pulmonary nodule raises concern for metastatic disease, although a single nodule cannot be definitively classified without histopathology or follow-up imaging.

## SPECIES

Canine

## BREED

Shih Tzu

## SEX

M

## AGE

11yr

## INTERPRETED BY

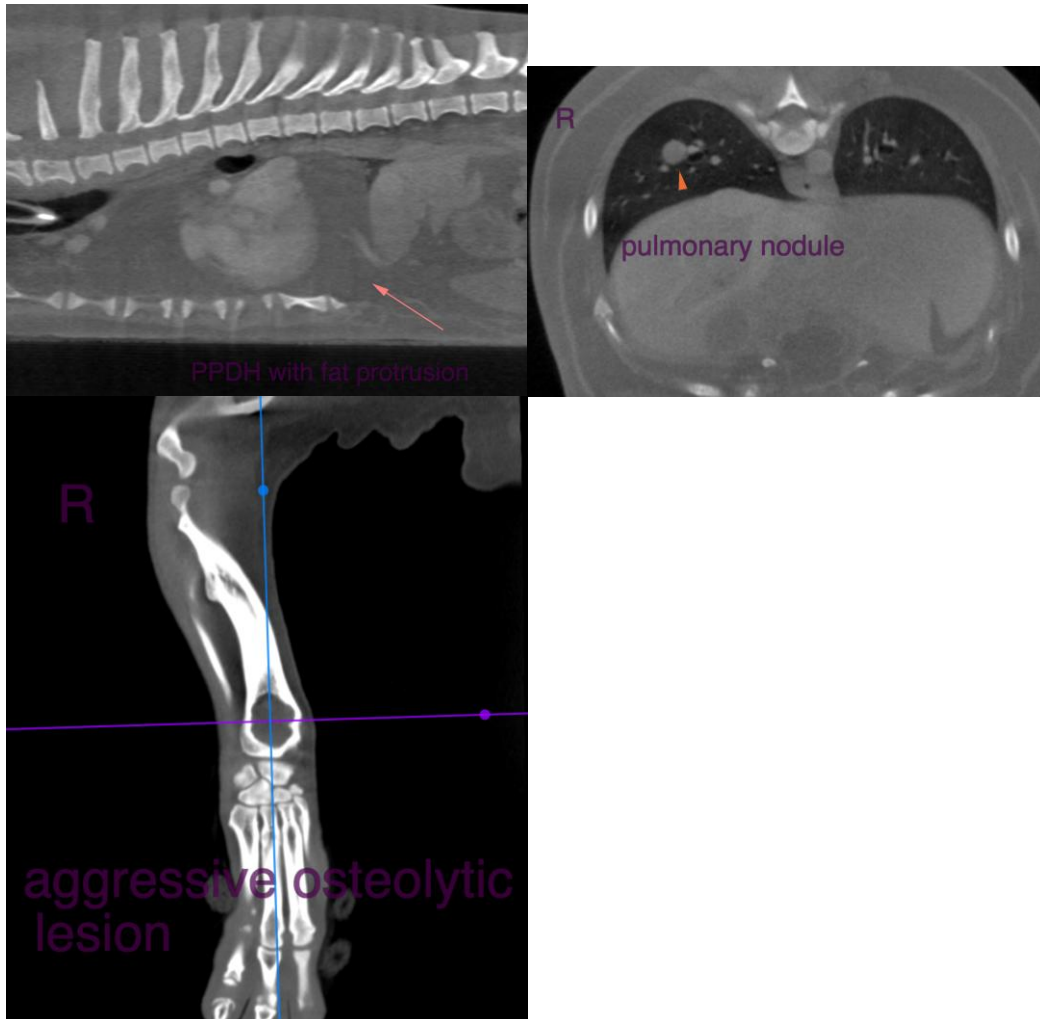
Nele Eley (Ondreka),  
DVM Dr. med. vet.,  
DipECVDI

## HOSPITAL NAME

Animal Trust  
Ellesmere

## REFERRING VET

Jenny Bowen Smith



## INVOICE

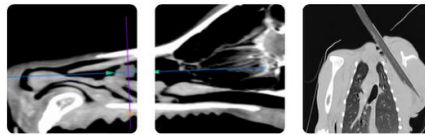
23749

## DATE

02/02/2026

The information and recommendations provided are based on the images presented by the referring veterinarian. No evaluation can be communicated regarding pathology that was not visible in the image/video clips provided.

Thank you for this referral. If the clinical or image interpretation does not parallel your findings or if I can be of any further assistance please contact me.



## PATIENT

Mealo Meara  
Nele Eley (Ondreka), DVM, Dr. med. vet., DipECVDI  
European Specialist in Veterinary Diagnostic Imaging, Cert. Radiology,  
Senior lecturer University of Giessen/Germany, Veterinary Faculty, Department of Radiology.  
[info@sonopath.com](mailto:info@sonopath.com)

## SPECIES

Canine

## BREED

Shih Tzu

## SEX

M

## AGE

11yr

## INTERPRETED BY

Nele Eley (Ondreka),  
DVM Dr. med. vet.,  
DipECVDI

## HOSPITAL NAME

Animal Trust  
Ellesmere

## REFERRING VET

Jenny Bowen Smith

## INVOICE

23749

## DATE

02/02/2026